

Safety and Efficacy of Transform for Noninvasive Lipolysis and Circumference Reduction of the Abdomen

Matthew Novak, MD
David Weir, NP-C
Rod J. Rohrich, MD

Summary: Noninvasive body contouring has seen a precipitous rise in popularity since its advent in the early 2000s. With this rise in popularity, there has been an expansion in the types and number of noninvasive devices for muscle hypertrophy and fat lipolysis. The Transform radiofrequency and electrical muscle stimulation device is a newly introduced device for noninvasive abdominal body contouring. The present study is a prospective clinical trial evaluating the efficacy of the Transform device on abdominal circumference. Fifteen patients were enrolled and received three treatment sessions with the Transform device. On average, patients saw changes in abdominal circumference (-0.43 cm, $P = 0.48$), caliper pinch thickness (-6.07 mm, $P = 0.0036$), and ultrasound fat thickness (-5.40 mm, $P < 0.001$) at 3 months posttreatment with minimal discomfort and high patient satisfaction. Ultimately, this study demonstrates that the Transform device is a safe and effective noninvasive option for fat lipolysis and muscular hypertrophy. (*Plast Reconstr Surg Glob Open* 2022;10:e4446; doi: [10.1097/GOX.0000000000004446](https://doi.org/10.1097/GOX.0000000000004446); Published online 20 July 2022.)

INTRODUCTION

A variety of noninvasive body contouring treatments are available for medical aesthetic indications, such as abdominal circumference reduction and fat lipolysis. These include devices based on optical energy, ultrasound technologies, radiofrequency (RF), cryolipolysis, suction-massage, or combined technologies.¹⁻³

RF technology for fat related indications is vastly used and clinically studied.^{1,4} RF delivers a thermal stimulus to the skin and subcutaneous adipose tissue causing neocollagenesis and thickening of the dermis and enhancement of lipolysis/fat cell metabolism, resulting in reduction of adipose tissue volume and circumferences.³ In contrast, electrical muscle stimulation (EMS) also known as neuromuscular electrical stimulation (NMES), is the application of current to elicit a muscle contraction. When applied to the abdomen, EMS has been shown to increase the strength of muscular contraction by about 14%–22%.^{5,6}

Clinical trials evaluating the effect of EMS on muscle hypertrophy and fat reduction have demonstrated promising results.^{7,8} The newly introduced Transform device combines alternating bipolar RF and EMS energies.

The current prospective study is intended to evaluate the safety and efficacy of the Transform device for noninvasive lipolysis and circumference reduction of the abdomen.

METHODS

This study was performed as an IRB approved prospective uncontrolled clinical trial to evaluate the efficacy of the Transform for noninvasive lipolysis and abdominal circumference reduction. Female and male patients aged 18–70 years with a body mass index (BMI) ≤ 30 kg/m² were included. Patients were excluded if they had any medical or surgical history that contraindicated the use of radiofrequency or EMS.

Each patient underwent five study visits, which included three treatments (each 2 weeks apart) and two follow-up visits (1 and 3 months posttreatment). Baseline standardized measurements were taken of the patients' abdominal circumference, fat thickness by ultrasound, abdominal contour (photographs), height and weight, and caliper pinch thickness.

From the Dallas Plastic Surgery Institute, Dallas, Tex.

Received for publication April 13, 2022; accepted June 2, 2022.

Protocol Number: DO609924A.

This work was supported by InMode Ltd.

Copyright © 2022 The Authors. Published by Wolters Kluwer Health, Inc. on behalf of The American Society of Plastic Surgeons. This is an open-access article distributed under the terms of the [Creative Commons Attribution-Non Commercial-No Derivatives License 4.0 \(CCBY-NC-ND\)](https://creativecommons.org/licenses/by-nc-nd/4.0/), where it is permissible to download and share the work provided it is properly cited. The work cannot be changed in any way or used commercially without permission from the journal.

DOI: [10.1097/GOX.0000000000004446](https://doi.org/10.1097/GOX.0000000000004446)

Disclosure: Dr. Rohrich receives instrument royalties from Eriem Surgical, Inc., and book royalties from Thieme Medical Publishing. The other authors have no financial interest to declare.

The criterion for successful treatment was a statistically significant reduction in abdominal circumference at 3 months follow-up compared with baseline. This endpoint was only calculated for patients who maintained a weight $\pm 3\%$ of their baseline measurement. Additionally, subjective satisfaction and comfort evaluations were obtained using a Likert scale.

RESULTS

There were 15 patients (13 women, 2 men) who met inclusion criteria and were enrolled in the study. BMI ranged from 18.7 to 25.8 kg/m² (average 22.68 kg/m²). BMI change during the study period ranged from -0.9% to 0.3%.

All 15 patients received three treatment sessions with the Transform device. Baseline patient measurements and the difference from baseline to 3 months after treatment are listed in Tables 1–3. Average changes from the baseline measurements to 3-month follow-up were as follows: abdominal circumference (-0.43 cm, $P = 0.48$), caliper pinch thickness (-6.07 mm, $P = 0.0036$), and ultrasound fat thickness (-5.40 mm, $P < 0.001$). Pretreatment and post-treatment ultrasound measurements are demonstrated in Figure 1. Patients' comfort level averaged between indifferent and comfortable for the first treatment session, comfortable for the second session, and between comfortable and very comfortable for the third session. There were no patients who reported being very uncomfortable. Average patient satisfaction score at 3 months posttreatment was 1.5 and ranged from 0 (indifferent) to 2 (very satisfied).

Only one patient experienced an adverse event during the study period. The patient experienced localized blistering at the treatment site that resolved with conservative management.

DISCUSSION

The Transform applicator is a hands-free medical aesthetic device applying combined bipolar RF energy and muscle activation. The noninvasive bipolar RF treatment targets the dermal and subdermal tissues. The EMS

Table 1. Ultrasound Measurements

Patient	Baseline Ultrasound (mm)	3-mo Ultrasound (mm)	Change (mm)	<i>P</i>
1	33.9	25.85	-8.05	
2	22	18.9	-3.1	
3	22.9	18.75	-4.15	
4	31.05	21.8	-9.25	
5	22.05	18.75	-3.3	
6	27.6	17.75	-9.85	
7	30.1	18.3	-11.8	
8	33.05	23.7	-9.35	
9	27.5	23.15	-4.35	
10	27.25	23.75	-3.5	
11	27.05	23.15	-3.9	
12	31.75	29.4	-2.35	
13	23.65	21.25	-2.4	
14	23.2	20.1	-3.1	
15	27.5	24.9	-2.6	
Average	27.37	21.97	-5.40	<0.001

Ultrasound fat measurements were taken at points lateral to the umbilicus. These points were marked and photographed for consistency in repeat measurements.

Takeaways

Question: Are the combination of radiofrequency and electrical muscle stimulation energies efficacious for circumference reduction of the abdomen?

Findings: On average, patients saw changes in abdominal circumference after treatment with the Transform device. Additionally, significant changes were observed in abdominal caliper pinch thickness and ultrasound fat thickness.

Meaning: The Transform device is a safe and effective non-invasive option for fat lipolysis and muscular hypertrophy.

repeatedly contracts muscles by passing electrical currents through electrodes contacting the treated body area.

The present study demonstrates that the Transform device can result in modest reductions in abdominal circumference in some patients. On average, the device had an insignificant effect (0.43 cm reduction, $P = 0.48$)

Table 2. Caliper Measurements

Patient	Caliper Pinch Thickness Baseline	Caliper Pinch Thickness 3 mo	Change	<i>P</i>
1	43.5	33.5	-10	
2	42.5	21.5	-21	
3	45	30.5	-14.5	
4	41.5	32	-9.5	
5	20.5	18.5	-2	
6	25.5	26	0.5	
7	40	36.5	-3.5	
8	43.5	34.5	-9	
9	26	23.5	-2.5	
10	27	27.5	0.5	
11	22.5	23.5	1	
12	38	30.5	-7.5	
13	25	29.5	4.5	
14	35.5	26.5	-9	
15	31.5	22.5	-9	
Average	33.83	27.77	-6.07	0.0036

Caliper pinch thickness measurements were taken at points lateral to the umbilicus. These points were marked and photographed for consistency in repeat measurements.

Table 3. Abdominal Circumference Measurements

Patient	Abdominal Circumference Baseline (CM)	Abdominal Circumference 3 mo (CM)	Change (CM)	<i>P</i>
1	88.33	88.33	0.00	
2	83.60	84.67	1.07	
3	95.33	93.00	-2.33	
4	90.67	88.67	-2.00	
5	85.00	80.00	-5.00	
6	87.67	87.00	-0.67	
7	100.00	101.67	1.67	
8	101.33	101.67	0.33	
9	98.33	97.67	-0.67	
10	92.33	94.33	2.00	
11	96.00	95.33	-0.67	
12	95.50	100.00	4.50	
13	93.33	92.33	-1.00	
14	92.00	88.67	-3.33	
15	87.00	86.67	-0.33	
Average	92.43	92.00	-0.43	0.4804734

Baseline abdominal circumference was measured initially at the widest part of the abdomen. At that time, a reference height from the floor was recorded to ensure consistent repeat treatment and measurements.

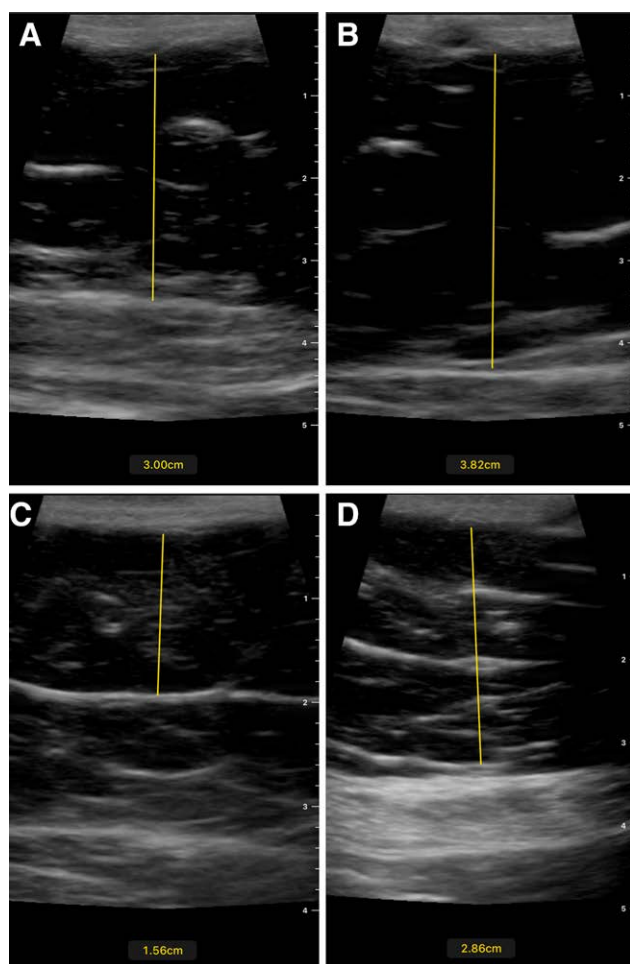


Fig. 1. Sonographic images of subcutaneous fat thickness from two treatment locations before and after treatment with the Transform radiofrequency and EMS device. A and B, Pretreatment images. C and D, The corresponding 3-month posttreatment images demonstrating reduction in subcutaneous fat thickness.

on abdominal circumference. This modest result may be related to muscular hypertrophy secondary to the simultaneous application of electrical muscular stimulation. This hypothesis seems to be supported by statistically significant improvements in the abdominal caliper pinch thickness and ultrasound fat thickness in the treated areas. Furthermore, the patients were on average between satisfied and very satisfied with the results and there was not a single patient who reported being disappointed with the results.

Regarding patient tolerance, the treatment seemed to be better tolerated, on average, with each successive treatment. Patients reported being between comfortable and very comfortable during the third treatment without a single patient reporting being very uncomfortable during any of the three treatment sessions.

The results of this study suggest that the Transform device is an effective modality for decreasing subcutaneous fat in the treatment areas. The effects on the muscle were not as well elucidated. Nonetheless, patients reported a high degree of treatment tolerance and satisfaction with the results. The isolated incident of posttreatment blistering resolved with conservative management without

sequela. These findings suggest that the Transform device is a safe and efficacious noninvasive treatment for abdominal contouring. This modality may be best suited for patients who desire abdominal muscular hypertrophy with decreased thickness of the overlying subcutaneous tissue, resulting in an improved appearance. Patients should be educated, however, that they may or may not achieve a modest reduction in abdominal circumference.

This study is not without limitations. The volume of the abdominal musculature was not evaluated and, therefore, cannot be excluded as a contributing factor to the modest results in abdominal circumference. Additionally, there was no control group to test the efficacy of radiofrequency and EMS in isolation. For this reason, it is not possible to draw conclusions about which of the modalities is benefiting the patient and what outcomes each is producing.

CONCLUSIONS

The Transform radiofrequency and EMS device for body contouring is a safe and efficacious noninvasive modality for patients looking to achieve better definition to their abdomen without surgery. Patients should be counseled regarding the benefits and limitations of the treatment. Particularly, the results may be less dramatic than an excisional procedure but spare the patient from the downtime, recovery, and scarring of a surgical procedure.

Rod J. Rohrich, MD

Dallas Plastic Surgery Institute
9101 North Central Expressway Suite 600
Dallas, TX 75231

E-mail: Rod.rohrich@dpsi.org
[@Rod.Rohrich](https://twitter.com/Rod.Rohrich)

REFERENCES

- Theodorou SJ, Chia CT, Dayan E, eds. *Emerging Technologies in Face and Body Contouring*. New York: Thieme Medical Publishers, Inc.; 2021:b-006-163730.
- Mulholland RS, Paul MD, Chalfoun C. Noninvasive body contouring with radiofrequency, ultrasound, cryolipolysis, and low-level laser therapy. *Clin Plast Surg*. 2011;38:503–520, vii.
- Adatto MA, Adatto-Neilson RM, Morren G. Reduction in adipose tissue volume using a new high-power radiofrequency technology combined with infrared light and mechanical manipulation for body contouring. *Lasers Med Sci*. 2014;29:1627–1631.
- Paul M, Blugerman G, Kreindel M, et al. Three-dimensional radiofrequency tissue tightening: a proposed mechanism and applications for body contouring. *Aesthetic Plast Surg*. 2011;35:87–95.
- Kamel DM, Yousif AM. Neuromuscular electrical stimulation and strength recovery of postnatal diastasis recti abdominis muscles. *Ann Rehabil Med*. 2017;41:465–474.
- Park M, Seok H, Kim SH, et al. Comparison between neuromuscular electrical stimulation to abdominal and back muscles on postural balance in post-stroke hemiplegic patients. *Ann Rehabil Med*. 2018;42:652–659.
- Jacob CI, Paskova K. Safety and efficacy of a novel high-intensity focused electromagnetic technology device for noninvasive abdominal body shaping. *J Cosmet Dermatol*. 2018;17:783–787.
- Kinney BM, Lozanova P. High intensity focused electromagnetic therapy evaluated by magnetic resonance imaging: safety and efficacy study of a dual tissue effect based non-invasive abdominal body shaping. *Lasers Surg Med*. 2019;51:40–46.